



EVALUATION OF MORPHOLOGICAL AND MORPHOMETRIC INDICATIONS OF TRACHEAL WALLS OF ONE-YEAR-OLD INFANTS

Sultonov Ravshan Komiljonovich

Saydullayeva Maftuna Azamatovna

Termez University of Economics and Service. Termez. Uzbekistan.

Аннотация: В статье освещены изменения трахеи и бронхов у развивающихся детей и проблемы их профилактики.

Ключевые слова: нарушения развития трахеи и бронхов, слабость бронхиальных стенок.

Relevance of the problem: Rapid development in the field of prenatal medicine has led to an increase in the number of various tracheobronchial interventions in the organs of the respiratory system of fetuses and infants. The study of the rules of organogenesis of the respiratory system allows a better understanding of the etiopathogenesis of congenital defects, and the reasons for the occurrence of structural variants of its structural components.

At the time of birth, the respiratory part of the respiratory tract is not yet fully formed: there are few alveoli, their wall is thicker than the alveolar wall of adults, and it contains very few elastic fibers. With the beginning of breathing, respiratory bronchioles begin to lengthen, new alveoli are formed in their walls. The size of the previously formed alveoli increases, barriers grow from their walls, which divide the space into parts - new alveoli are formed. The size of the previously formed alveoli increases, barriers grow from their walls, which divide the space into parts - new



alveoli are formed. The most active alveologenesis takes place in the first 18 months of a child's life, the formation of new alveoli continues until the age of 5. The correct formation of alveoli is caused by the active development of microcirculatory flow and formed elastic fibers in the presence of a complete surfactant system. The full development of the elastic structure in the lungs is completed only by the age of 18 [1].

When examining the respiratory function, a sign of moderate shortness of breath was often found in the trachea, and in these large bronchi (53.7%), if there were no violations of the sign of shortness of breath, a decrease in the air flow rate prevailed in the initial part. mandatory term (68.1%) [3-4].

To study the characteristics of the anatomy of the lower respiratory tract in the fetus, 50 fetuses from 15 to 23 weeks of age were examined. They were obtained during the termination of a normal pregnancy for social reasons and as a result of ante-intranatal fetal death from acute hypoxia.

New information was obtained about the features of the macro-microscopic structure of the lower respiratory system, their microtopography, skelotope, syntopy, which required microsurgical intervention in fetal surgery [5-6].

During the study, the cervical length increased by 48% and the uterine body increased by 25% during thoracic surgical examination during early pregnancy [7].

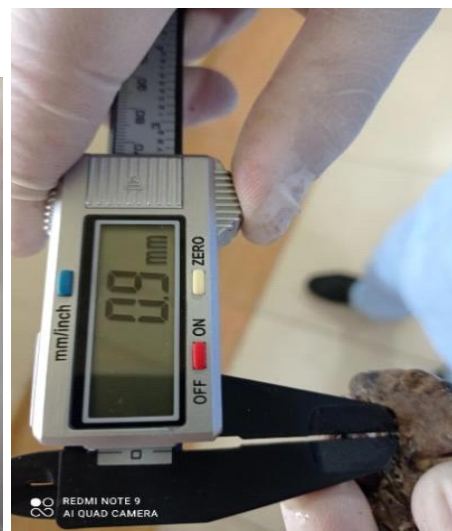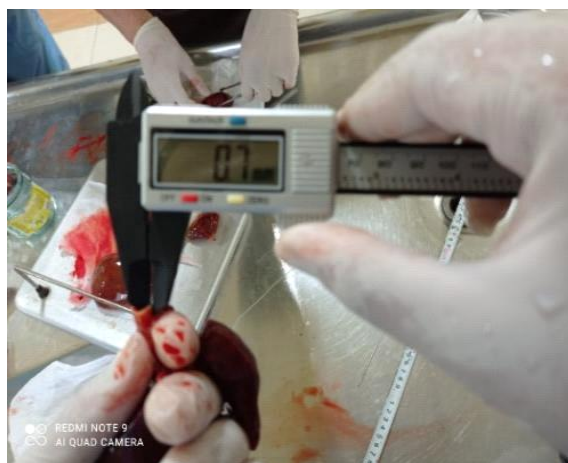Embryonic development of the respiratory system in the period of 18-19 weeks of trachea and right subarachnoid artery was 92% at the level of Th1-2, and the lowest growth intensity corresponds to 0-1.9% at 22-23 weeks in Th1-2 [8].

Taking into account the above, it is necessary to conduct research aimed at studying the development of the trachea in postnatal ontogeny in infants under one year of age.



The purpose of the study: to evaluate the morphological parameters of the tracheal walls of infants under one year of age.

Research materials and methods: The investigation was conducted on the corpses of infants under one year of age admitted in the 3rd quarter of 2021-2022 at the Republican Pathological Anatomy Center. Infants who died under the influence of various factors, but whose respiratory system did not change, were studied in the cadavers of children without diseases of the pulmonary bronchial passages, who died mainly from heart defects and other causes. The causes of death and the main disease were determined in the results of pathological anatomy. Examination material was taken from the following part of the trachea: autopsy material was taken from the upper and lower part of the trachea and studied. Instrumental (with the help of barbell), general histological, histochemical, morphometric and statistical research methods were used in our research. The obtained materials were fixed in formalin and then 3-5 μm sections were prepared. They were stained with hemotoxylin-eosin, Schick's reaction, and Van-Gieson methods (**Figure 1**).



A B



Figure 1. Measurement of the trachea of a one-year-old baby using an electronic die. (a-measurement of the thickness of the tracheal wall of a young person, b-measure the inner diameter of the trachea of a young person).

Results of the study: When babies reach 1 year old, the large airway of the respiratory system, i.e. the trachea, changes from a funnel shape to a cylindrical shape. The mucous membrane of the trachea is thinner compared to other parts of the bronchial path, its covering epithelium contains more smooth-surfaced epithelium than ciliated epithelium, according to scientific literature, it is 1.5 times more. In our study, it was found that the lining epithelium of the tracheal mucosa is relatively thin and covered with a single layer of prismatic epithelium. A large number of smooth surface epithelium was observed in the covering epithelium. The height of both epithelial cells is relatively small, prismatic in shape, the nuclei are arranged more irregularly, most of the nuclei do not touch the basal layer, it was found that they are round and oval in shape.

It was found that the basal membrane is composed of thin fibrous structures and is fused with the underlying connective tissue private plate. It was confirmed that there was an infiltration of lymphohistiocytic cells in the tissue of the private plate. In the deep layers of the private plate, it was found that there are smooth muscle cells consisting of a single tuft located in a circular direction. After it, i.e., in the deep layers, there are rows of smooth muscle cells.

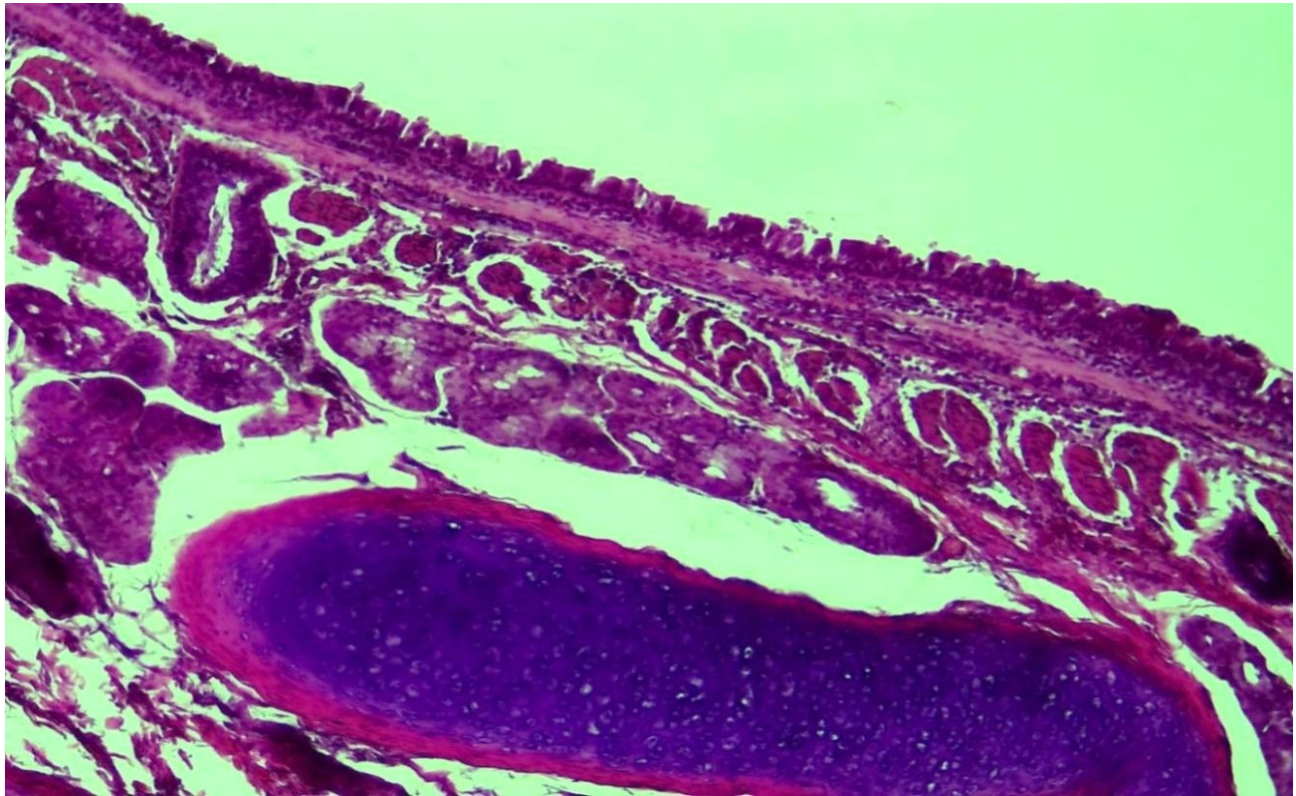


Figure 2. 12 month period. Trachea, mucous membrane (1) protective plate (2) is thin at the top, and the larynx is dense (3). Produced by the hemotoxylin-eosin method. Enlarged image in 10x40 size

It was observed that the thickness of the tufts was different, and a thin connective tissue interstitium took place between them. Private glands of the trachea are located under the muscle bundles, the difference from the previous periods is that the gland cells are relatively large, the cells are fat and the apical part is vacuolated.

The larynx is surrounded by a dense connective tissue membrane. It was found that the intermediate substance in the togai tissue was stained with dark ink color, there were relatively few cells, and some of them were vacuolated.

When the histochemical method was used to determine the connective tissue bundles on the tracheal wall, it was found that the connective tissue fibers were increased and densely located around the private plate, submucous layer, and larynx (Figure 3).



1\

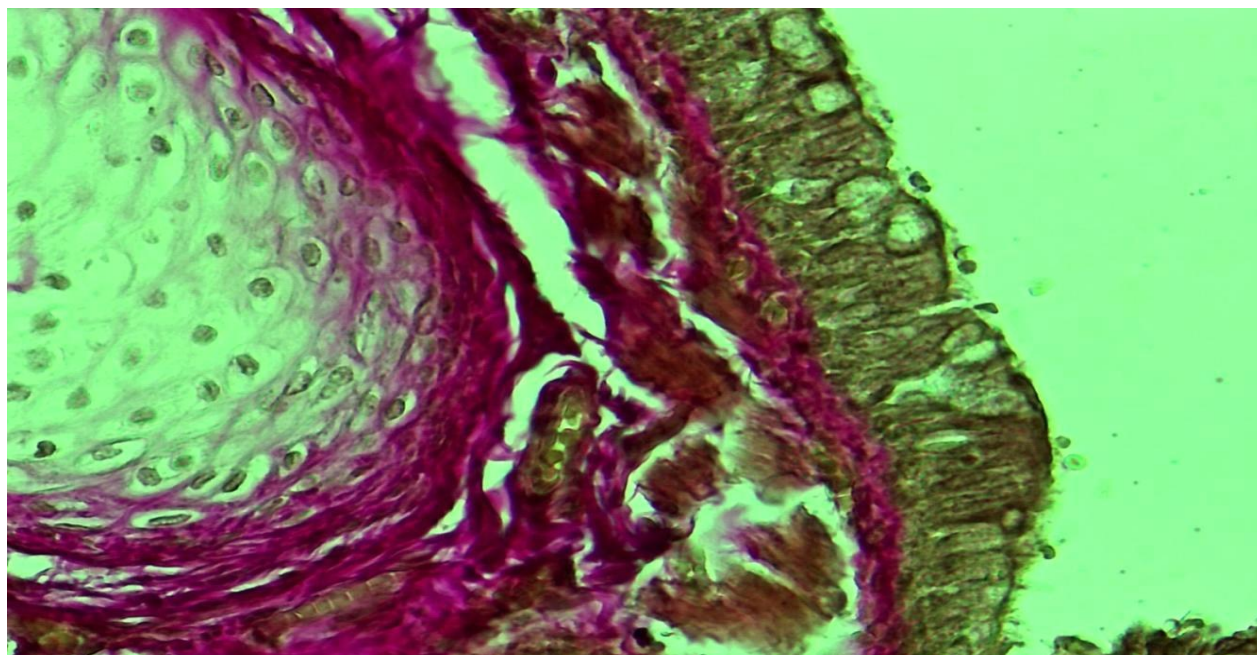


Figure 3. 12 month period. Proliferation and dense placement of connective tissue bundles in the wall of the trachea(1). Stained by the Van Gieson method. Enlarged image in 10x40 size

It should be noted that the analysis of the morphometric parameters of the tracheal walls of babies under one year of age shows that the trachea of newborn babies is on average 4.1 ± 0.16 cm, the width is 0.9 ± 0.03 cm. . The mucous membrane is thin, delicate, has few glands, poorly developed.

Since the mucous membrane is rich in blood and lymph vessels, the inflammatory process is often extinguished.

Covering epithelium contains 1.7 times more smooth surface epithelia than ciliated epithelium.

When babies reach one year of age, the trachea changes from funnel-shaped to cylindrical.



At the age of one year, it was found that the connective tissue fibers around the tracheal wall, submucosal layer, and larynx are more and more densely located.

Conclusion: From newborn to one year of age, the tracheal wall consists of poorly developed tissue in all layers, the covering epithelium is multi-layered to single-layered, the private plate changes from unformed connective tissue to formed tissue, the larynx from sparse chondroid and cellular structure to dense chondromatous tissue with small cells. it was found that it is going around.

Заключение: От новорожденного до года стенка трахеи состоит из слабо развитой ткани во всех слоях, покровный эпителий многослойный до однослойного, собственная пластинка изменяется от неоформленной соединительной ткани до сформированной ткани, гортань от разреженной хондройдной и ячеистой структуры до плотной хондроматозной ткани с мелкими ячейками. Было обнаружено, что она циркулирует.

The trachea and bronchial tree is a specialized ventilation system in humans, which becomes smaller and narrower until it reaches the lungs, and the respiratory bronchioles connect to the alveoli. The narrowing of these tree-like structures to such an extent ensures that air reaches the alveoli easily and completely during breathing.

References:

1. Sultanov R.K., Sodikova Z.Sh. Indicators of postnatal ontogenetic development of pulmonary bronchi in infants under one year of age. Methodical recommendation. Tashkent, 2022, B. 32.
2. Sultanov R.K., Sodikova Z.Sh., Arsenova M.A. Morphometric indicators of the tissue structures of the bronchial wall layers in the dynamics of the early postnatal period in one-year-old infants // Academic research in modern science International scientific-online conference. - USA. - 2022. - R. 155-159.



3. Skiba V.P. Tracheobronchial dyskinesia (expiratory prolapse of the membranous wall of the trachea and bronchi). Pulmonology. 1996;(2):54-57.
4. Sultanov.R.K, Sodikova.Z.Sh, Boboyorov.S.U. Dynamics of fat cells of the bronchial tree mucosa in postnatal ontogenesis. // Central Asian Journal of Medical and Natural Science (CAJMNS) – Tashkent. Volume 2 No. 4, 2021. S. 182-184.
5. Lutsai E.D., Shcherbakov S.M., Zheleznov L.M. Mikhailov, S.N. Nekotorye voprosy fetalnoy anatomii nijnix dikhatelnyx putey. // Morphological journal. - 2011. - No. 2. - S. 50 - 56.
6. Lyashchenko D.N. Anatomy and topography of human trunk in early reproductive period ontogenesis // Fundamentalnye issledovaniya.- 2012.-№10-2.-S. 254-257.
- 7.Sadovnikova I.V., Zudov A.V. Sovremennye podkhody k etiopathogeneticheskoy therapy bronxoobstruktivnyx zabolevaniy v pediatricheskoy praktike // Vestnik novykh meditsinskikh tekhnologiy - 2015 - T. 22, No. 1 – S. 27
8. Mikhailov S. N. Topograficheskaya anatomy trachei i glavnyx bronchov human v rannem plodnom periode ontogenesis. Abstract. Orenburg-2008