



IS IT NECESSARY TO REMOVE WISDOM TEETH AND THEIR PREVENTION

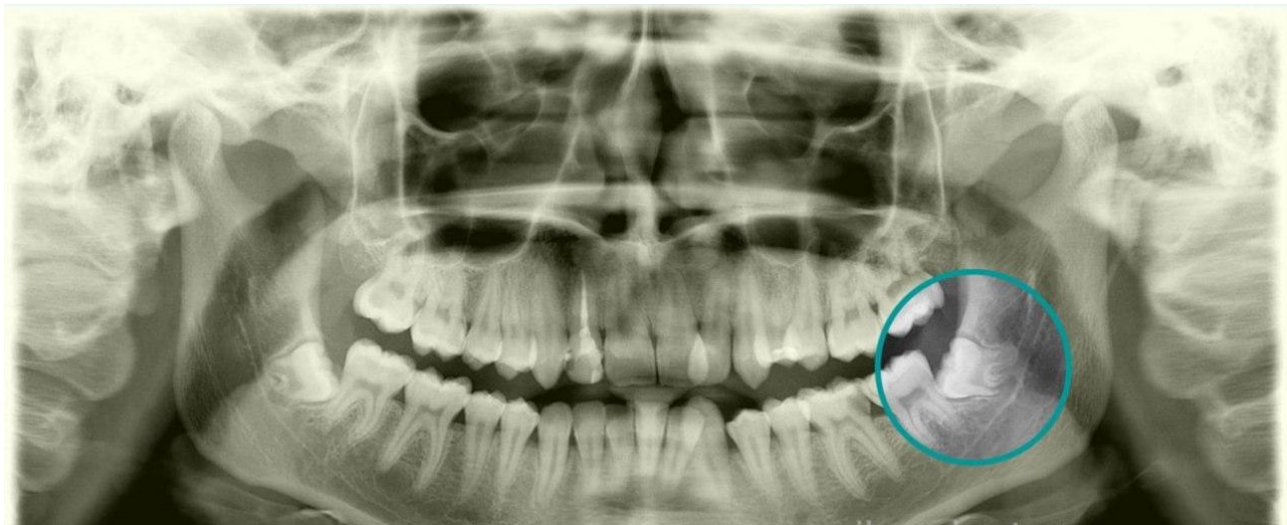
Farkhatov Sunnatillokhan Furkhatovich

Clinic Resident of the Department of Orthopedic Dentistry
Samarkand State Medical University Samarkand, Uzbekistan.

Akhmedov Alisher Astanovich

DSc, Head of the Department of Orthopedic Dentistry
Samarkand State Medical University Samarkand, Uzbekistan

Wisdom teeth are the 8th tooth in a row, the third molar (there are 4 in total), usually erupt at the age of 17-25 years (sometimes later, less often earlier, sometimes they do not erupt — they remain retentive). Incompletely erupted teeth are called "semi-refined". Wisdom teeth are laid in humans in the prenatal period of development (in the womb), like others. Their absence is considered a variant of the norm in dentistry, not a pathology.



Currently, it is generally believed that the third molar is a rudimentary organ due to a change in diet (a decrease in the consumption of hard and hard food). In confirmation of this, there has recently been an increase in cases of absence of the rudiment of this tooth — the primary adentia of the third molar. This is also evidenced by dystopia, retention and, often, the non-physiological shape of the crown and roots of this tooth.



It is believed that wisdom teeth are so called because they appear much later than other teeth, at an age when a person's mental development is considered perfect, and the development of human wisdom begins.

During the cutting of the lower wisdom teeth, when only part of the tooth is visible, purulent inflammation often occurs in the formed pocket ("hood") between the gum and the tooth — pericoronitis. Excision of the overhanging gum is recommended for the treatment of pericoronitis. If pericoronitis often recurs, then wisdom tooth extraction is indicated.

It often happens that wisdom teeth, due to lack of space in the jaw arch, can incorrectly erupt and take a non-physiological position. The third molars, especially the upper ones, can cut into the buccal side and injure the mucous membrane of the cheek. It is also possible to erode the lower wisdom teeth with a tilt towards the tooth standing next to it. Because of this, food gets into the gap between the second and third molars. Due to the impossibility of adequate hygienic treatment of this area, caries of the adjacent tooth, increased deposits of hard (tartar) and soft plaque, gingivitis or pericoronitis are possible. Teeth with such pathologies are usually removed.[1]

With normal eruption and under the condition of a physiological shape, wisdom teeth can be used in prosthetics as a supporting tooth for a bridge prosthesis or to fix a clamp or attachment on it in removable prosthetics.

Rarely (more often in representatives of the Australoid race) there are additional, fourth molars[2].

What are wisdom teeth?

Teeth are classified by location and function. The sharper teeth in the front of the mouth – flat incisors and rounded canines – tear food into smaller pieces, while the more voluminous and powerful molars are designed for crushing. Adults have 16 molars – 4 c on each jaw on each side.

From infancy to early adolescence, the first baby teeth erupt. Then they gradually fall out, and in their place permanent ones appear, with which a person will have to live the rest of his life. Not everyone has wisdom teeth. Research shows that about



53% of the population aged 25 and over have at least one, but some may never have one in their entire lives. In men, the "eights" erupt more often than in women.

What are wisdom teeth for?

Wisdom teeth are generally not needed by people. In fact, most researchers consider them rudimentary. This means that they once served a purpose, but they no longer serve, we can quite do without them.

The primitive diet of our ancestors consisted of a large number of raw plants, hard nuts and hard meat, and wisdom teeth were necessary to grind these foods for proper digestion. Today, modern industrial cooking methods and cutlery have eliminated the need for such powerful chewing "equipment". As humans have adapted to dietary changes, our bodies have undergone some small evolutionary changes. So, our jaws have become smaller, and there is simply no room for wisdom teeth.

Where are the wisdom teeth.

Wisdom teeth erupt in the very back of the mouth, just behind the second molars. If you count from a large incisor, they will turn out to be the eighth in a row, which is why they are often called "eights". People who have all four wisdom teeth have one in each quadrant— upper left, lower left, upper right and lower right. And only such people have a complete dental formula of 32 teeth (4 x 8), but any formula within 28-32 teeth can be considered normal nowadays.

What are the signs of wisdom teeth eruption.

The fact that a person does not see the "eight" does not mean that he does not have them, they can remain in the jaw throughout his life and not erupt. Such teeth can only be seen on an X-ray.

However, if the third molars begin to cut, there are several obvious manifestations. There may be only one of the following signs, there may be several:

Redness or swelling of the gums behind the last molars (second molars).

A feeling of distension in the posterior parts of the jaw.

Jaw pain or hypersensitivity to pain.



Pain in the face area due to the fact that the wisdom teeth squeeze the nerves.

Ear pain that is not related to inflammation in it.

White spots behind the second molars. They can be the tops of the "eights" that erupt through the gums.

How to care for healthy wisdom teeth.

If the "eights" have been preserved and the dentist did not find any complaints about them after the examination, special attention should be paid to these teeth. They are located in the back of the mouth, so natural cleaning methods may not work well in relation to them.

In addition to regular visits to the dentist, you should:

Brush your teeth two to three times a day. It may be difficult to get to the back of the wisdom teeth, but you need to try.

Floss your teeth once a day to clean the interdental spaces. You can also use toothpicks or interproximal brushes (small brushes that fit between the teeth) for hard-to-reach places.

Use antiseptic mouthwash. It is advisable to choose alcohol-free formulations, they help reduce the risk of developing xerostomia (dry mouth).

What problems can be associated with wisdom teeth?

Ear pain that is not related to inflammation in it.

White spots behind the second molars. They can be the tops of the "eights" that erupt through the gums.

How to care for healthy wisdom teeth

If the "eights" have been preserved and the dentist did not find any complaints about them after the examination, special attention should be paid to these teeth. They are located in the back of the mouth, so natural cleaning methods may not work well in relation to them.

In addition to regular visits to the dentist, you should:



Brush your teeth two to three times a day. It may be difficult to get to the back of the wisdom teeth, but you need to try.

Floss your teeth once a day to clean the interdental spaces. You can also use toothpicks or interproximal brushes (small brushes that fit between the teeth) for hard-to-reach places.

Use antiseptic mouthwash. It is advisable to choose alcohol-free formulations, they help reduce the risk of developing xerostomia (dry mouth).

What problems can be associated with wisdom teeth ?

Regardless of whether wisdom teeth are visible or not, they can cause oral health problems. The uncut "eights" are called retained ("delayed"), and sometimes they cause more problems than the erupted ones.

One of the main problems is infection. The peculiarities of the location of the "eights" make them vulnerable to caries, pericoronitis, pulpitis, and periodontitis.

Signs of a wisdom tooth infection:

Pain or hypersensitivity in the tooth area

Swelling of the gums

Bleeding gums

The release of white liquid from the parotid space

Unpleasant taste in the mouth

Bad breath

Pain in the jaw

Difficulty swallowing, opening the mouth or speaking

Treatment of wisdom tooth infection

There are several treatment options for the "eights" infection and their choice depends on the severity of the situation and the position of the tooth. Antibiotics may be prescribed in order to cope with the infection. A therapeutic or surgical dental procedure can then be performed to prevent repeated infections.



So, a decision can be made to restore the tooth, fill the cavity or gap around the eruption site in order to minimize the number of pockets of the mucous membrane and other spaces convenient for bacteria.

In some cases, surgery, including partial or complete tooth extraction, is the best way to keep this part of the oral cavity clean and prevent further discomfort.

Can a wisdom tooth be removed without infection

Yes, they can. Since they are usually very large and "clutter up" the mouth, shifting or even damaging other teeth, the dentist may advise removing the "eights" even before they finally erupt.

In addition, the third molars can be removed before an orthodontic procedure, such as the installation of braces, to ensure that the wisdom teeth do not erupt at the most inopportune moment and do not negate all the painstaking work to form the correct bite.

Teenagers are recommended to undergo an examination before surgery to remove wisdom teeth. Healing is better if surgery is performed before the roots of the tooth are fully formed and the final ossification of the growth zones in the jaw occurs.

How to remove wisdom teeth.

The degree of difficulty with which a dentist or maxillofacial surgeon can remove wisdom teeth depends on their position and stage of development. The attending physician will be able to form an idea of the situation only after examination and X-ray examination.

A wisdom tooth that has completely erupted through the gum can be removed about as easily as any other tooth. The retained "eight", which is hidden under the gum or did not come out of the jawbone at all, is more difficult to get. A gum dissection and deeper intervention will be required.

Often in such a situation, the wisdom tooth is sawed and removed in small parts, rather than entirely, in order to minimize the collateral damage.

How to behave after wisdom tooth extraction

Often in such a situation, the wisdom tooth is sawed and removed in small parts, rather than entirely, in order to minimize the collateral damage.



How to behave after wisdom tooth extraction

After the removal of wisdom teeth, the speed of recovery depends on the degree of complexity of the removal – whether it was a simple extraction of a fully erupted tooth compared to a partially or completely retented "eight".

During the first 24 hours:

Bleeding may occur within a few hours after removal. To control it, place a piece of clean, damp gauze on an empty tooth socket and bite firmly. Apply constant pressure for about 45 minutes. A moistened tea bag is a completely effective alternative. The tannic acid in tea promotes the formation of healing blood clots. Repeat this process if slight bleeding continues; if severe bleeding continues, consult a dentist or maxillofacial surgeon. Within 24 hours after tooth extraction, do not rinse or spit, avoid "sucking" actions (for example, do not drink drinks through a straw and do not smoke) and avoid hot liquids (such as coffee or soup).

There is usually swelling of the face in the area where the tooth was removed. To minimize swelling, apply a piece of ice wrapped in a cloth to this area of the face according to the schedule: 10 minutes of reception and 20 minutes of break. Repeat as needed during this first 24-hour period.

Painkillers such as paracetamol or ibuprofen can be taken for minor pain. If necessary, a dentist or maxillofacial surgeon can prescribe more potent painkillers.

Antibiotics that may have been prescribed by a doctor prior to tooth extraction (to treat any active infection around the wisdom tooth being removed) should continue to be taken until the full course of treatment prescribed by a specialist is completed.

Food should be limited to a liquid diet until the numbness from anesthesia passes. Eat soft foods for several days. Also, avoid drinking alcohol if you are taking narcotic painkillers at the same time.

Continue brushing your teeth, but do not touch the teeth directly adjacent to the removed "eight" for the first 24 hours. On the second day, resume brushing your teeth gently. Do not use mouthwashes — they can irritate the extraction site.

After 24 hours:

Facial swelling in the area of tooth extraction should be treated with heat after the first 24 hours with ice. Apply a damp, warm towel to the area for 20 minutes, then



take a 20-minute break and repeat the cycle as needed. Keep in mind that edema usually peaks 2-3 days after the procedure.

Rinse your mouth with warm salt water (1/2 teaspoon of salt per glass of warm water) after eating and before going to bed. Do not use mouthwashes unless the dentist has prescribed otherwise.

Sutures, if they were applied and nonresorbable (non-degradable in the body) material was used, should be removed by the attending physician after about 1 week. Before the operation, you can ask what kind of suture material will be used.

Watch for signs of a dry hole. This condition requires treatment from your doctor.

Complete healing is not a fast process, it may take up to several months. However, as a rule, after a couple of weeks the wound is tightened enough to return to the previous rhythm of life and a normal diet.

List of used literature:

1. Asrorovna, X. N., Baxriddinovich, T. A., Bustanovna, I. N., Valijon O'g'li, D. S., & Qizi, T. K. F. (2021). Clinical Application Of Dental Photography By A Dentist. *The American Journal of Medical Sciences and Pharmaceutical Research*, 3(09), 10-13.
2. Ugli, A. A. A., & Bustanovna, I. N. (2024). STUDY OF THE CONDITION OF PARODONT IN PERIODONTITIS IN FETAL WOMEN. *European International Journal of Multidisciplinary Research and Management Studies*, 4(05), 149-156.
3. Kizi, J. O. A., & Bustanovna, I. N. (2024). FAMILIARIZATION WITH THE HYGIENIC ASSESSMENT OF THE CONDITION OF THE ORAL MUCOSA IN ORTHOPEDIC TREATMENT. *European International Journal of Multidisciplinary Research and Management Studies*, 4(05), 89-96.



4. Bustanovna, I. N. (2024). Determination of the Effectiveness of Dental Measures for the Prevention of Periodontal Dental Diseases in Workers of the Production of Metal Structures. *International Journal of Scientific Trends*, 3(5), 108-114.
5. Bustanovna, I. N. (2022). Assessment of clinical and morphological changes in the oral organs and tissues in post-menopause women. *Thematics Journal of Education*, 7(3).
6. Bustanovna, I. N., & Berdiqulovich, N. A. (2022). ПРОФИЛАКТИКА И ЛЕЧЕНИЯ КАРИЕСА У ПОСТОЯННЫХ ЗУБОВ. *JOURNAL OF BIOMEDICINE AND PRACTICE*, 7(1).
7. Bustanovna, I. N. (2024). PATHOGENESIS OF PERIODONTAL DISEASE IN ELDERLY WOMEN. *Лучшие интеллектуальные исследования*, 21(3), 25-29.
8. Bustanovna, I. N. (2024). TO STUDY THE HYGIENIC ASSESSMENT OF THE CONDITION OF THE ORAL MUCOSA DURING ORTHOPEDIC TREATMENT. *Лучшие интеллектуальные исследования*, 21(1), 9-15.
9. Bustanovna, I. N. (2024). CLINICAL AND LABORATORY CHANGES IN PERIODONTITIS. *Journal of new century innovations*, 51(2), 58-65.
10. Bustanovna, I. N. (2024). Morphological Changes in Oral Organs and Tissues in Women after Menopause and their Analysis. *International Journal of Scientific Trends*, 3(3), 87-93.
11. Bustanovna, I. N. (2024). Hygienic Assessment of The Condition of The Oral Mucosa After Orthopedic Treatment. *International Journal of Scientific Trends*, 3(3), 56-61.



12. Bustanovna, P. I. N. (2024). Further Research the Features of the Use of Metal-Ceramic Structures in Anomalies of Development and Position of Teeth. *International Journal of Scientific Trends*, 3(3), 67-71.
13. Bustanovna, I. N. (2024). The Effectiveness of the Use of the Drug " Proroot MTA" in the Therapeutic and Surgical Treatment of Periodontitis. *International Journal of Scientific Trends*, 3(3), 72-75.
14. Bustanovna, P. I. N. (2024). Research of the Structure of Somatic Pathology in Patients with Aphthous Stomatitis. *International Journal of Scientific Trends*, 3(3), 51-55.
15. Bustanovna, I. N., & Abdusattor o'g, A. A. A. (2024). Analysis of Errors and Complications in the Use of Endocal Structures Used in Dentistry. *International Journal of Scientific Trends*, 3(3), 82-86.
16. Bustanovna, I. N. (2024). Complications Arising in the Oral Cavity after Polychemotherapy in Patients with Hemablastoses. *International Journal of Scientific Trends*, 3(3), 62-66.
17. Bustanovna, I. N., & Sharipovna, N. N. (2023). Research cases in women after menopause clinical and morphological changes in oral organs and their analysis. *Journal of biomedicine and practice*, 8(3).
18. Bustonovna, I. N., & Sharipovna, N. N. (2023). Essential Factors Of Etiopathogenesis In The Development Of Parodontal Diseases In Post-Menopasis Women. *Eurasian Medical Research Periodical*, 20, 64-69.
19. Fakhridin, C. H. A. K. K. A. N. O. V., Shokhruh, S. A. M. A. D. O. V., & Nilufar, I. S. L. A. M. O. V. A. (2022). ENDOKANAL PIN-KONSTRUKSIYALARNI ISHLATISHDA ASORATLAR VA XATOLAR TAHLILI. *JOURNAL OF BIOMEDICINE AND PRACTICE*, 7(1).



- 20.Очилов, Х. У., & Исламова, Н. Б. (2024). Особенности артикуляции и окклюзии зубных рядов у пациентов с генерализованной формой повышенного стирания. *SAMARALI TA'LIM VA BARQAROR INNOVATSIYALAR JURNALI*, 2(4), 422-430.
- 21.Ortikova, N., & Rizaev, J. (2021, May). The Prevalence And Reasons Of Stomatophobia In Children. In *E-Conference Globe* (pp. 339-341).
- 22.Ortikova, N. (2023). ANALYSISOF ANESTHESIA METHODS FOR DENTAL FEAR AND ANXIETY. *Центральноазиатский журнал академических исследований*, 1(1), 8-12.
- 23.Ortikova, N. K. (2023). DENTAL ANXIETY AS A SPECIAL PLACE IN SCIENTIFIC KNOWLEDGE. *SCHOLAR*, 1(29), 104-112.
- 24.Исламова, Н. Б. (2024). ПАРОДОНТ КАСАЛЛИКЛАРИДА ОРГАНИЗМДАГИ УМУМИЙ ЎЗГАРИШЛАРНИ ТАҲЛИЛИ ВА ДАВОЛАШ САМАРАДОРЛИГИНИ ТАКОМИЛЛАШТИРИШ. *ОБРАЗОВАНИЕ НАУКА И ИННОВАЦИОННЫЕ ИДЕИ В МИРЕ*, 43(7), 18-22.
- 25.Islamova, N. B., & Chakkonov, F. K. (2021). Changes in the tissues and organs of the mouth in endocrine diseases. *Current Issues in Dentistry*, 320-326.
- 26.Исламова, Н. Б., & Исломов, Л. Б. (2021). Особенности развития и течения заболеваний полости рта при эндокринной патологии. *ББК*, 56, 76.
- 27.Исламова, Н. Б., & Назарова, Н. Ш. (2023). СУРУНКАЛИ ТАРҚАЛГАН ПАРОДОНТИТ БИЛАН КАСАЛЛАНГАН ПОСТМЕНОПАУЗА ДАВРИДАГИ АЁЛЛАРНИНГ ПАРОДОНТ ТЎҚИМАСИНИНГ ДАВОЛАШ САМАРАДОРЛИГИ ОШИРИШ. *ЖУРНАЛ СТОМАТОЛОГИИ И КРАНИОФАЦИАЛЬНЫХ ИССЛЕДОВАНИЙ*, 4(2).



- 28.Исламова, Н. Б. (2024). ПАРОДОНТИТ КАСАЛЛИГИДА ОРГАНИЗМДАГИ УМУМИЙ ВА МАҲАЛЛИЙ ЎЗГАРГАН КЎРСАТКИЧЛАРНИНГ ТАҲЛИЛИ. *Журнал гуманитарных и естественных наук*, (8), 23-27.
- 29.Islamova, N. B., & Sh, N. N. (2023, May). STUDY OF CHANGES IN PERIODONTAL DISEASES IN POSTMENOPAUSAL WOMEN. In *Conferences* (pp. 15-17).
- 30.Исламова, Н. Б., & Назарова, Н. Ш. (2023, May). Совершенствование диагностики и лечения хронического генерализованного пародонтита у женщин в период постменопаузы. In *Conferences* (pp. 13-15).
- 31.Islamova, N. B., & Nazarova, N. S. (2023). IMPROVING THE DIAGNOSIS AND TREATMENT OF CHRONIC GENERALIZED PERIODONTITIS IN POSTMENOPAUSAL WOMEN. *Conferences*.
- 32.Исламова, Н. Б. (2023). Гемодинамика тканей пародонта зубов по данным реопародонтографии.
- 33.Исламова, Н. Б., & Назарова, Н. Ш. (2023). МЕТОДЫ ИССЛЕДОВАНИЯ ЗАБОЛЕВАНИЙ ПАРОДОНТА У ЖЕНЩИН, НАХОДЯЩИХСЯ В ПЕРИОДЕ ПОСТМЕНОПАУЗЫ. In *АКТУАЛЬНЫЕ ВОПРОСЫ СТОМАТОЛОГИИ* (pp. 334-338).
- 34.Исламова, Н. Б. (2024). Complications Arising in the Oral Cavity after Polychemotherapy in Patients with Hemablastosis. *International Journal of Scientific Trends*, 3(3), 76-81.
- 35.Islamova, N. B. (2022). CHANGES IN PERIODONTAL TISSUES IN THE POSTMENOPAUSAL PERIOD. In *Стоматология-наука и практика, перспективы развития* (pp. 240-241).



36. Назарова, Н., & Исломова, Н. (2022). Этиопатогенетические факторы развития заболеваний пародонта у женщин в периоде постменопаузы. *Профилактическая медицина и здоровье*, 1(1), 55-63.
37. Иргашев, Ш. Х., & Исламова, Н. Б. (2021). Применение и эффективность энтеросгеля при лечении генерализованного пародонтита. In *Актуальные вопросы стоматологии* (pp. 305-310).
38. Иргашев, Ш., Норбутаев, А., & Исламова, Н. (2020). Эффективность энтеросгеля при лечении генерализованного пародонтита у ликвидаторов последствий аварии на чернобыльской АЭС. *Общество и инновации*, 1(1/S), 656-663.
39. Исламова, Н. Б. (2016). Сравнительная оценка противовоспалительных цитокинов крови в развитии заболеваний полости рта при гипотиреозе. *Наука в современном мире: теория и практика*, (1), 41-44.
40. Исламова, Н. Б., Шамсиев, Р. А., Шомуродова, Х. Р., & Ахмедова, Ф. А. (2014). Состояние кристаллообразующей функции слюны при различных патологиях. In *Молодежь и медицинская наука в XXI веке* (pp. 470-471).
41. Исламова, Н., & Чакконов, Ф. (2020). Роль продуктов перекисного окисления липидов и противовоспалительных цитокинов крови в развитии заболеваний полости рта при гипотиреозе. *Общество и инновации*, 1(1/s), 577-582.
42. Исламова, Н., Хаджиметов, А., & Шакиров, Ш. (2015). Роль продуктов перекисного окисления липидов и противовоспалительных цитокинов крови в развитии заболеваний полости рта при гипотиреозе. *Журнал проблемы биологии и медицины*, (1 (82)), 41-44.



43. Исламова, Н. Б., & Чакконов, Ф. Х. (2021). Изменения в тканях и органах рта при эндокринных заболеваниях. In *Актуальные вопросы стоматологии* (pp. 320-326).
44. Nazarova, N. S., & Islomova, N. B. (2022). postmenopauza davridagi ayollarda stomatologik kasalliklarining klinik va mikrobiologik ko'rsatmalari va mexanizmlari. *Журнал "Медицина и инновации"*, (2), 204-211.
45. Nazarova, N. S., & Islomova, N. B. (2022). postmenopauza davridagi ayollarda stomatologik kasalliklarining klinik va mikrobiologik ko'rsatmalari va mexanizmlari. *Журнал "Медицина и инновации"*, (2), 204-211.
46. Sulaymonova, Z. Z., & Islamova, N. B. (2023, May). TAKING IMPRESSIONS IN THE ORAL CAVITY AND THEIR REDUCTION. In *Conferences* (pp. 21-23).
47. Sharipovna, N. N., & Bustonovna, I. N. (2022). Etiopatogenetic factors in the development of parodontal diseases in post-menopasis women. *The american journal of medical sciences and pharmaceutical research*, 4(09).
48. Sarimsokovich, G. M. (2023). LATEST METHODS OF STUDY OF PERIODONTAL DISEASE IN WOMEN. *European International Journal of Multidisciplinary Research and Management Studies*, 3(10), 242-250.
49. Sarimsokovich, G. M. (2023). MODERN METHODS OF RESEARCH OF PERIODONTAL DISEASES IN WOMEN. *Open Access Repository*, 4(2), 632-639.
50. Sarimsokovich, G. M. (2023, May). CLINICAL EFFICIENCY OF THE GUIDED REGENERATION METHOD OF TISSUE IN THE TREATMENT OF CHRONIC PERIODONTITIS OF THE MIDDLE DEGREE. In *Conferences* (pp. 11-13).
51. Sarimsokovich, G. M. (2024). METHODS FOR STUDYING PERIODONTAL DISEASES IN WOMEN IN THE POSTMENOPAUSE PERIOD. *Лучшие интеллектуальные исследования*, 18(4), 36-42.



52.Sarimsokovich, G. M. (2024). IMPROVING THE EFFECTIVENESS OF PREVENTION AND TREATMENT OF INFECTIOUS PROCESSES OF THE ORAL CAVITY IN PEOPLE USING DENTAL PROSTHETICS. *Лучшие интеллектуальные исследования*, 18(4), 31-35.

53.Содикова, Ш. А., & Исламова, Н. Б. (2021). Оптимизация лечебно-профилактических мероприятий при заболеваниях пародонта беременных женщин с железодефицитной анемией. In *Актуальные вопросы стоматологии* (pp. 434-440).

Sharipovna, N. N., & Bustanovna, I. N. (2022). Assessment of clinical and morphological changes in the oral organs and tissues in post-menopause women. *Frontline medical sciences and pharmaceutical journal*, 2(05), 60-67.